

ASSOCIATED GRAVES' DISEASE AND PLUMMER'S DISEASE

Nebojša Paunkovic and Jane Paunkovic

INTRODUCTION

From the clinical point of view, hyperthyroidism is generally presented as diffuse hyperactivity of thyroid tissue induced by autoimmune stimulation (Graves' disease), or as the consequence of one, or more hyperactive autonomous nodules (Plummer's disease). These two entities are relatively perceivable in clinical routine. Thyroid scintigraphy of the patient with Graves' disease, presents a pattern of a diffusely enlarged gland with homogenous distribution of radioactive tracer. In Plummer's disease, one nodule ("toxic adenoma") or rarely few nodules (toxic nodular goiter), are presented as scintigraphically "hot" nodules with complete suppression of paranodular tissue.

Occasionally, some scintigraphic findings that could not be so simplified are registered. Thyroid glands of some patients with Graves' disease present nodules that can accumulate radioactive tracer of the comparable intensity to paranodular tissue (warm nodules). This occurrence of the functioning adenoma in Graves' disease has been named by Charks (1,2) » Marine-Lenhart syndrome«. Rational assumption of coexistent presence of Graves' disease and Plummer's disease is comprehensible. It is difficult to confirm such association, since both hyperfunctioning autonomous nodules and stimulated paranodular tissue accumulate radioactive tracer intensively. Nevertheless, consequent melioration of Graves' disease may unveil presence of hyperfunctioning autonomous nodules (toxic adenoma). Successive appearance of Graves' disease and Plummer's disease is diagnostically simple and some cases have been reported (3,4,5,6,7). Differential diagnosis of some untypical scintigraphic findings of non-immune hyperthyroidism could also be presented as a problem. Diffuse toxic goiter does not always have pathological substrate of Graves' disease. Occasionally, hyperactive autonomous follicles are dispersed throughout the gland – disseminated thyroid autonomy (8), and sometimes in addition to visible hyperfunctioning nodule (toxic adenoma), a part of autonomous paranodular tissue is also presented (9).

The aim of this study was to assort those cases of a distinct hyperthyroidism with neither clearly diffuse, nor focal scintigraphic findings, and to establish associated presence of Graves' disease and Plummer's disease with the special focus.

PATIENTS AND METHODS

From the total of 1337 patients with hyperthyroidism 17 patients were selected for the additional investigation of associated (simultaneous or successive) appearance of the autoimmune (Graves' disease) and autonomus (Plummer's disease) hyperthyroidism. Investigated group consisted of 15 female and 2 male patients, age from 44 to 69 years (average 58,6) at presentation. Retroactive analysis of the patients data from the date of the last control (september 1999- March 2000) to the first registration was performed. Duration of the analysed period was from 20 years to 18 months. These results are presented as anterograde, follow up study.

Diagnosis of hyperthyroidism was made upon clinical signs of hypermetabolism, thyroid hormones serum levels (TT₄, TT₃, FT₄, FT₃) and ultra sensitive TSH (Delfia, Pharmacia). TSH receptor antibodies were determined by TRAK Assay (BRAHMS Diagnostica, former Henning) and occasionally by cAMP stimulation on animal thyrocytes. ¹³¹I uptake tests were performed in order to exclude findings of the patients in hyperthyroid phase of destructive thyroiditis and iatrogen hyperthyroidism (iodine, thyroxin). Scintigraphy of the thyroid was performed 24 hours after oral application of ¹³¹I using rectilinear scanner Pho-Dot II, Nuclear Chicago, or 30 minutes after intravenous application of ^{99m}Tc-pertechnetate using scintillation gamma camera Pho Gamma IV Searle, USA, and Open Diacam, Siemens, recently. Triiodothyronin supession test was utilized to confirm focal thyroid autonomy in euthyroid patients. Thyroid nodules were examined by palpation and ultrasonography (ALOCA, linear probe 7.5 MHz).

Based on the clinical, ultrasonography and scintigraphic findings, hormone and immunological testing, all patients were classified in groups:

- Graves' disease
 - immunogenic diffuse toxic goiter
 - Marine-Lenhart syndrome (Graves' disease with functioning adenoma)
- Plummer's disease (thyroid gland with autonomous hyperfunctioning nodule-one, rarely two)
- Toxic adenoma (palpable nodule with intensive uptake of the radioactive tracer and invisible paranodular tissue, with clinical and laboratory signs of non immune hyperthyroidism)
- Autonomous hyperfunctioning nodule in euthyroid state ("hot" nodule partially suppressed paranodular tissue, normal or slightly elevated free thyroid hormones)
- Associated Graves' and Plummer's disease

RESULTS

Results of the investigation are presented in tables, and few interesting examples are illustrated by scintigraphic findings.

In Table 1 are presented: diagnosis, clinical and laboratory findings at the time of the first medical examination ("at presentation").

Table 1. Diagnoses and important patients data at the first examination

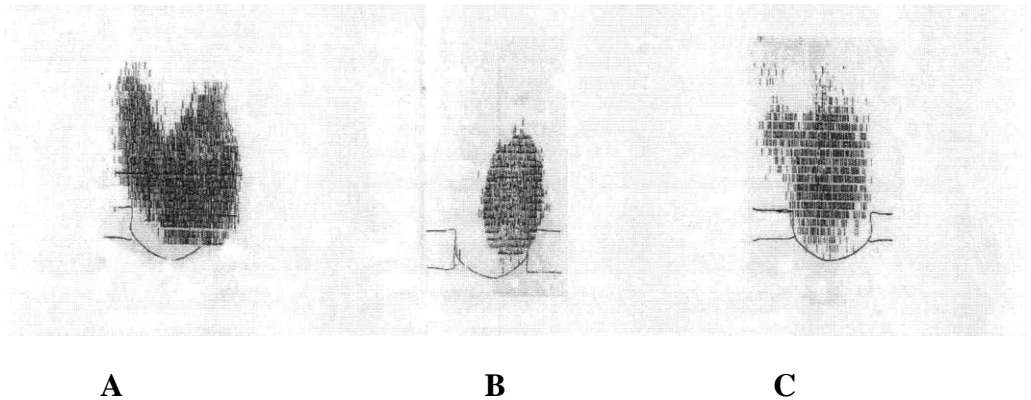
HYPERTHYR	GRAVES' DISEASE		PLUMMER'S DISEASE		ASSOCIATED
	Dif toxic goiter	Marine-Lenh.	Toxic adenoma	AFN	Grav.+Plumm.
Number	2	3	1	6	5
Free hormones	high	High	high	Sligh.elev.	High (4), Norm (1)
US TSH mU/l	0.01	0.01	0,01	0.05-0,1	0,01
TRAb (incid)	2/2	1/3	0/1	0/6	3/5
Optalmop (inc)	1/2	2/3	0/1	0/6	3/5
TRAb or opht	2/2	3/3	0/1	0/6	5/5

Table 2. Results of follow-up study: the appearance of new diagnostic criteria for diagnosis of »associated hyperthyroidism«

No	Inic	Sex	I dg	I Th	Outcome I	Dg criter	Th II	Outcome II	Dg criter
1	S.M	M	DTG	MMI	Remiss	Hot lesion	RAI	Remiss	
2	N.B	F	DTG	MMI	Remiss	AFN		Relaps	Diff. TRAb
3	MK	F	ML	MMI	Remiss	AFN		Hyperthyr	AFN
4	BM	F	ML	MMI	Remiss	AFN		Hyperthyr	AFN
5	I.D	F	ML	MMI	Remiss	AFN		Hyperthyr	Diff. TRAb
6	VD	F	TA	RAI	Euthyr			**Relaps	Diff. Opht.
7	RB	F	AFN		Euthyr			Hyperthyr	Diff. TRAb
8	SV	F	AFN	RAI	Euthyr			*Hyperthyr	Diff. Opht
9	MG	F	AFN		Euthyr			Hyperthyr	Diff
10	MD	F	AFN		Euthyr			Hyperthyr	Diff. TRAb
11	NB	F	AFN		Euthyr			Hyperthyr	Diff
12	ML	F	AFN		Euthyr	Diff. TRAb			

** 12 months after RAI

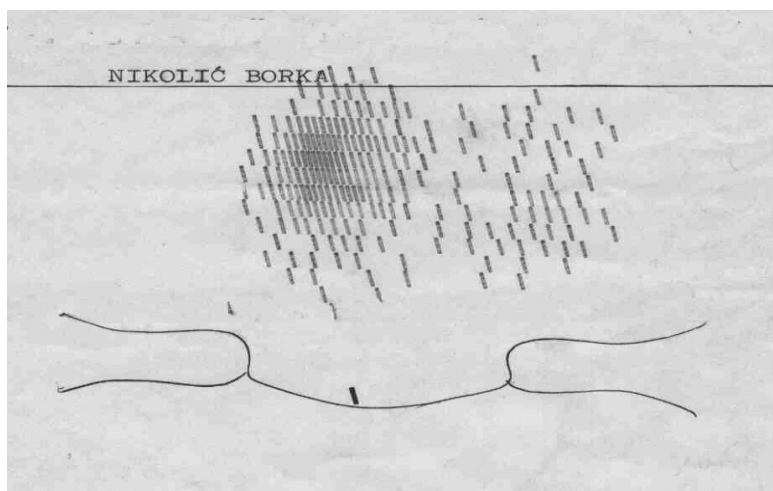
* 6 years after RAI

**Figure 1.** Patient M.D. 46 years aged, female.

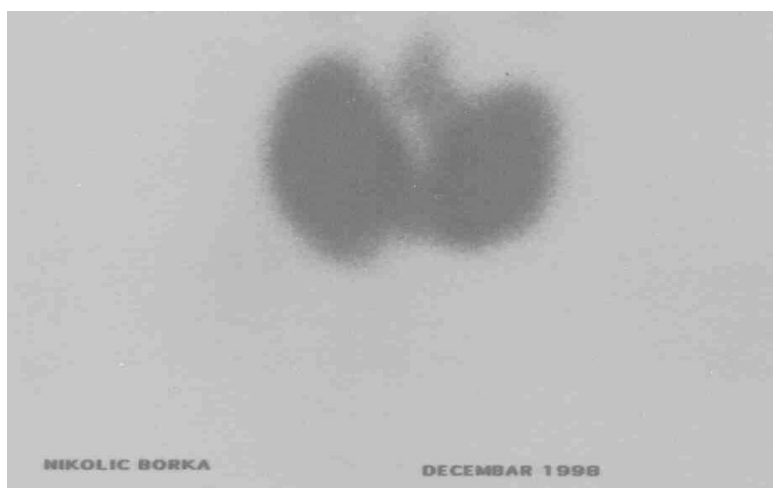
1A. Data from 1984 yr. Diffuse thyroid scintiscan (^{131}I) with »warm« nodule in left lobe. Hypermetabolic state, total T4 210 nmol/l. TBII strongly positive (310 U/l). Th: Methimazole (MMI). Remission and cessation of MMI 1985.

1B. Control check-up 1990 yr. Scintiscan: autonomous hyperfunctional nodule (AFN). T4 normal (130 nmol/l), T3 elevated (3,5 nmol/l) and TBII negative (5 U/L). Th: RAI 22 mCi.

1C. Control check-up 1992 yr. Scintiscan: »warm« nodule, T4 normal (120 nmol/l).



A September



B December

Figure 2. Patient N.B. 47 years aged, female. Treated for Graves' disease (MMI) before 36 months. In remission 18 months. Clinically and echosonography before treatment: diffusely enlarged thyroid gland.

2A. Control check-up: scintiscan: »hot« nodule in right thyroid lobe with partially suppressed paranodular tissue (AFN?). Total thyroid hormones normal ($T_4=137$ nmol/l; $T_3=2$ nmol/l). TBII negative (5 U/l).

2B. Three months later: relaps! Thyroid scintiscan: diffuse pattern with intensive uptake of ^{99m}Tc pertechnetate in both lobes and pyramidal lobe. TSH= 0,01 mU/l (suppressed); FT3= 122 pmol/l (high); TBII 45 U/l (positive). Th: MMI (in course).

Table 3. The results of follow-up study in patients with primary diagnosis of »associated hyperthyroidism«

Br	Inic	Sex	I Th	Follow-up time	Outcome	II Th	Outcome
1	S.L.	F	RAI	7 months	Cold nod. euth.		
2	G.C.	F	-	7 years	Hyperthyr	RAI	AFN, euth.
3	S.L.	F	RAI	7 months	Hyperthyr	RAI	AFN, euth.
4	M.N.	F	MMI	6 months	TA	RAI	Warm nod, euth.
5	B.M.	M.	MMI	12 months	Under treat.	contin	Warm nod, hyper

Abbreviations (for Tables):

DTG – diffuse toxic goiter

ML – Marine-Lenhart syndrome

TA – toxic adenoma

AFN – Autonomous functioning nodule

MMI – methimazole

RAI – radioactive iodine

Diff – diffuse scintigraphic pattern

Opht - opthalmopathy

TRAb – TSH-R antibody

Two patients with apparent Graves' disease, diffuse toxic goiter, had no detectable thyroid nodule or "hot lesion" on thyroid scintigram. Patients classified as "Marine-Lenhart syndrome" had Graves' disease and "warm" thyroid nodule. One patient with Plummer's disease had "toxic adenoma" and other six patients had autonomous functioning nodule (AFN) with euthyroid clinical state (solitary "hot" nodule on scintigraphy with visible paranodular tissue). By T₃ suppression test in three patients from the last group, functional autonomy of thyroid nodule was confirmed. Patients with diagnoses of "associated hyperthyroidism" (Graves' plus Plummer's disease) had solitary "hot" nodule, less visible paranodular tissue and immunogenic signs of Graves' disease.

For 12 patients with "non-associated" hyperthyroidism "at presentation" (Graves' or Plummer's disease separately), the evolution of the disease was analyzed (follow-up study). The change of diagnosis was performed based on appearance of some "new diagnostic criterion" (table 2).

In the Figure 1 and 2 some results of follow-up study are presented.

Analysis of the evolution of disease was performed also in five patients with associated immunogenic and non-immunogenic hyperthyroidism. Some significant data is presented on table 3.

DISCUSSION

We have performed retrospective analysis of the data of patients treated for hyperthyroidism in last twenty years. Cases of iatrogenic hyperthyroidism and destructive thyroiditis were not

included in this study. Total of 1042 patients with Graves' disease(1015 with diffuse goiter, and no nodules and 27 patients with Graves' disease and nodular goiter) and 272 patients with Plummer's disease (263 patients with solitary nodule and 9 with multinodular toxic goiter). Based on the follow-up study (from 18 months to 20 years) distinct group of 23 patients was postulated as group with associated (simultaneous or successive) Graves' disease and Plummer's disease. For 17 patients of the last group by detailed follow-up of relevant diagnostic parameters, associated Graves' disease and Plummer's disease is documented.

At the first diagnostic evaluation final results of only 5 out of 17 patients were designated as associated Graves' disease and Plummer's disease (Table 1). Patients data and follow-up results are presented in Table 3. Other 12 patients have previously been classified as Graves' disease (5 patients) and Plummer's disease (7 patients) (Table 1). After the appearance of "new diagnostic criterion" those 12 patients were included in this "associated hyperthyroidism" group (Table 2). For the cases classified as Graves' disease (diffuse toxic goiter), the "new diagnostic criterion" was appearance of "hot lesion" or "hot" nodule, often in relapse of hyperthyroidism subsequent to medicament treatment. In Marine-Lenhart syndrome, the "new diagnostic criterion" is apparently disclosed AFN in established remission. Patients with Plummer's disease (7 patients) present intense hyperthyroidism as the "new diagnostic criterion" associated with scintigraphic vizualization of previously suppressed paranodular tissue, positive TRAb findings and/or ophthalmopathy. Only two of these seven were treated by radioiodine for AFN.

Presence of the focal autonomy in patients with Graves's disease has been reported by numerous authors. Barbieri reported one case of the patient with autonomous thyroid nodule and unilateral exophthalmos (5), and Vento (10) reported 4 cases of the patients with "hot" nodules who developed hyperthyroidism with diffuse hyperactivity of thyroid tissue. Recently, in one paper of Carnell et Valente, authors are reporting that 1% of patients with Graves' disease have autonomous nodule (11). Kasagi reported focal autonomy in patients with euthyroid Graves's disease(12) and in hypothyroid patients with TSBAb (13). There are also observations of the Graves' disease primary manifested on thyroid scintigraphy as only one thyroid lobus (14,15). In one case report, after the therapy of Graves' disease with RAI, previously present non functional nodule ("cold") was disclosed as toxic adenoma (4). More frequent are reports of Graves' disease with detectable TRAb after the therapy of toxic adenoma with RAI (6,7,14,16). Our findings illustrate the evolution of the functioning (no autonomous) adenoma in Graves' disease ("Marine-Lenhart syndrome)(1,2) into AFN as well as simultaneous presence of autoimmune and autonomous hyperthyroidism.

The purpose of this study was neither to elucidate etiology of the focal lesions in Graves' disease, nor to register Graves' disease after the therapy of toxic adenoma with RAI. There are numerous reports on those subjects by very eminent investigators (3,6, 7, 8, 9, 16) as well as, on the intercrossing of autoimmune and autonomous factors in hyperthyroidism (17,18,19). The purpose of this report was only to indicate simultaneous presence of the immune and autonomous hyperthyroidism documented by routine thyroid scintigraphy in the course of clinical follow-up as reported previously (20).

REFERENCES

- 1 Charkes D N 1972 Graves' disease with functioning nodules (Marine-Lenhart syndrome). J Nucl Med 13:885-892.
- 2 Blondeau Ph, Daou RG, Rene L 1976 Nosologie des hyperthyroidies nodulaires – Place du syndrome de Marine-Lenhart. Nouv Press Med 5:411-414.

- 3 Hirsch C, Laubenbacher C, Langhammer HR, Spyra L, Senekowitsch-Schmidtke, Schwaiger M 1995 Incidence of immunogenic thyroid disease following treatment of Plummer's disease with I-131 therapy. *Eur J Nucl Med* 22:79 (abstr 298).
- 4 Simova N 1994 A case of adenoma toxicum after radioiodine therapy of hyperthyreosis. *Mak Med Preg* 36:122-123.
- 5 Barbieri RC 1977 Thyroid nodule with contralateral exophtalmos. Questions and Answers. *JAMA* 238:1789.
- 6 Chiovato L, Santini F, Vitti P, Bendinelli G, Pinchera A 1994 Appearance of thyroid stimulating antibody and Graves' disease after radioiodine therapy for toxic nodular goiter. *Clin Endocrinol (Oxford)* 40:803-806.
- 7 Weiss M, Gorges R, Hirsch C, Bader J, Tatsch K, Hahn K 1999 Auftreten einer immunogene Hyperthyreose nach Radioiod-Therapie fokaler Schilddrusenautonomien. Ergebnisse einer multizentrischen Erhebung. *Med Klin* 94:239-244.
- 8 Studer H, Hunziker HR, Ruchti C 1978 Morphologic and functional substrate of thyrotoxicosis caused by nodular goiters. *Am J Med* 65:227-234.
- 9 Peter HJ, Studer H, Forster R, Gerber H 1982 The pathogenesis of »hot« and »cold« follicles in multinodular goiters. *J Clin Endocrinol Metab* 55:941-946.
- 10 Vento JA, Slavin JD Jr, Reardon GE, Spencer RP 1986 Graves' disease. Initial presentation with exophtalmos and solitary hot nodule. *Clin Nucl Med* 11:404-406.
- 11 Carnell NE, Valente WA 1998 Thyroid nodules in Graves' disease: classification, characterization, and response to treatment. *Thyroid* 8:571-576.
- 12 Kasagi K, Hidaka A, Misaki T, Myamoto S, Takeuchi R, Sakahara H, Sasayama S, Iida Y, Konishi J 1994 Scintigraphic findings of the thyroid in euthyroid ophtalmic Graves' disease. *J Nucl Med* 35:811-817.
- 13 Kasagi K, Hatabu H, Miyamoto S, Takeuchi R, Misaki T, Sakahara H, Iida Y, Konishi J 1994 Scintigraphic findings of the thyroid in hypothyroid patients with blocking-type TSH-receptor antibodies. *Eur J Nucl Med* 21:962-967.
- 14 Regalbuto C, Salamone S, Scollo C, Vigneri R, Pezzino V 1999 Appearance of anti TSH-receptor antibodies and clinical Graves' disease after radioiodine therapy for hyperfunctioning thyroid adenoma. *J Endocrinol Invest* 22:147-150.
- 15 Sakata S, Fuwa Y, Goto S, Fukui M, Yuasa H, Takuno H, Sarui H, Matsui I, Ogawa T, Sasano N 1993 Two cases of Graves' disease with presentation of unilateral diffuse uptake of radioisotopes. *J Endocrinol Invest* 16:903-907.
- 16 Niepomniszcz H, Pitoia F, Goodall C, Manavela M, Bruno O.D 2000 Development of Graves' disease after radioiodine treatment for a toxic nodule. Is the hyperthyroidism always triggered by 131-I therapy? In: Peter F, Wiersinga W, Hostalek U. *The Thyroid and Environment*, Schattauer, Stuttgart-NewYork, 339-340.
- 17 Sellshopp CH, Derwahl M, Schaube H, Hamelmann H 1987 Evidence of autoimmune pathogenesis in autonomous thyroid adenoma. *Acta Endocrinol (Copenh)* 281 (suppl):355-357.
- 18 Van Sande J, Lamy F, Lecocq R, Mirkine R, Rosmans P, Cochaux P, Mockel J, Dumont JE 1988 Pathogenesis of autonomous thyroid nodules: in vitro study of iodine and adenosine 3'5'- monophosphate metabolism. *J Clin Endocrinol Metab* 66:570-579.
- 19 Dremier S, Coppee F, Delange F, Vassart G, Dumont JE 1996 Thyroid autonomy: Mechanism and clinical effects. *J Clin Endocrinol Metab* 81:4187-4193.
- 20 Paunkovic N, Paunkovic J 1998 Associated Graves' disease and Plummer's disease: Variant of Marine-Lenhart syndrome or distinct clinical entity? 25th Annual Meeting of the European Thyroid Association- Clinical Thyroid Day. Athens 1998 (abstract book).